Scholars Academic Journal of Pharmacy
Abbreviated Key Title: Sch Acad J Pharm
ISSN 2347-9531 (Print) | ISSN 2320-4206 (Online)
Journal homepage: http://saspublishers.com

OPEN ACCESS
Pharmacy

# To Evaluate Intestinal Anti-Inflammatory Activity of Alcoholic Extract of Polyherbal Plant Extracts in Experimental Model of Acute Colitis Model

Raunak Srivastava[1*], Dr. Jitender K Malik[1], Dr. Deepak Jhariya[1], Dr. Sunita Arya[1], Dr. Indranil K Yadav[1]

[1]Faculty of Pharmacy, P.K. University, Shivpuri, Madhya Pradesh, India

**DOI:** https://doi.org/ 10.36347/sajp.2025.v14i09.006 | **Received:** 05.10.2025 | **Accepted:** 24.11.2025 | **Published:** 30.11.2025

***Corresponding author:** Raunak Srivastava
Faculty of Pharmacy, P.K. University, Shivpuri, Madhya Pradesh, India

**Abstract** **Original Research Article**

Ulcerative colitis is an idiopathic chronic relapsing–remitting inflammatory disorder that affects the colon and rectum. The present study was an attempt to investigate *in-vivo* intestinal anti-inflammatory activity by using the polyherbal plant extact which is combination of roots of Hemidesmus indicus and seeds of *Centratherum anthelminticum.* Inflammation was successfully produced by intra-rectal administration by using 4% glacial acetic acid in albino Wistar rats via intra rectal route for assessment of acute intestinal anti- inflammatory effect. Positive control animals were only treated with vehicle and simultaneously animals of other groups oral treatment with two doses (500mg/kg & 1000mg/kg b.w) and Prednisolone (2mg/kg b.w) Polyherbal Plant Extracts treated of animals significantly reduced in a colon score compared to positive control group of animals. Significant decrease in Myeloperoxidation, and Lipidperoxidation as compared to positive control group of animals. Polyherbal Plants Extracts treatment likely to be responsible for the observed significant intestinal anti-inflammatory effect via anti-oxidant mechanism.

**Keywords:** Ulcerative colitis, *Hemidesmus indicus,* Centratherum anthelminticum, Acute colitis, Myeloperoxidation, Lipidperoxidation, Polyherbal Plant Extracts.

**Copyright © 2025 The Author(s):** This is an open-access article distributed under the terms of the Creative Commons Attribution **4.0 International License (CC BY-NC 4.0)** which permits unrestricted use, distribution, and reproduction in any medium for non-commercial use provided the original author and source are credited.

## INTRODUCTION

Ulcerative colitis and Crohn's disease, clinically defined as inflammatory bowel disease (IBD) is chronic inflammatory disease of the colon and rectum. Although etiology of the disease has not yet been clear, possible etiological factors are genetic influences, Immunological abnormalities and environmental agents. In the recent years, role of reactive oxygen species (ROS) in thepathogenesis of IBD has been stressed [1-3].

Available evidences from the literature strongly suggests cascade of free radical products, subsequent lipid peroxidation reducing cellular anti-oxidant capacity resulting in colonic inflammation. Further, it has been shown that number of inflammatory mediators such as ROS, lysosomal enzymes and products of arachidonic acid metabolism are secreted from granulocytes in the inflamed mucosa in IBD [1,4-5]. IBD is a chronic, remittent or progressive inflammatory conditions that may affect the entire gastrointestinal tract and the colonic mucosa, respectively, and are associated with an increased risk for colon cancer. IBD has long been appreciated to have a genetic basis and likely involves a response of the immune system to some environmental agent(s). The discordance of IBD among monozygotic twins and the development of IBD in immigrants to high prevalence countries and in countries undergoing rapid Westernization also highlight the importance of environmental factors in disease pathogenesis [6].

*Hemidesmus indicus*. R. Br, is a twining shrub, whose roots has been used in folk medicine, *ayurvedic* and *unani* medicine and are prescribed for disorder/disease affecting haemopoetic system [7], GIT, respiratory system skin disease, infection disease and inflammatory disorders. Review of literature revealed extensive investigation to justify its use in folklore/ traditional system of medicine. Among the most important pharmacological property reported include hepatoprotective, Nephroprotective, Cardioprotective, Antiinflammatory [8-9].

*Centratherum anthelminticum* (L) Kuntze seeds is popular in indigenous system of medicine for treatment of various ailments. Among its several uses its useful uses in curing ulcers and inflammatory swelling,

intestinal colic [10]. The current investigation envisages to assess protective effect of alcoholic extract of seeds of *Centratherum anthelminticum* in view of paucity of studies reporting its usefulness in IBD, despite possessing acute and sub-acute anti- inflammatory effect [11], and reported flavonoid content [12]

## MATERIALS AND METHODS

**Plant Material and Extraction**

Methanolic extract of Polyherbal plant extract (roots of Hemidesmus indicus & seeds of Centratherumant anhelminticum stored in air tight container in door refrigerator section of the refrigerator at $4^0$C till further use. Administered of plant extract in 1:1 ratio.

**Experimental animals:** Selection of Test animals: Healthy, Albino Wistar rats (either sex) weighing between 170-200 gms randomly assigned for.

**Pharmacological investigations**

**Acetic Acid-induced Colitis in Rats:** The male Wistar albino rats (170 - 230 gm) were selected and randomized into five groups of six animals in each group. Group 1 served as normal or untreated animals, group 2 was positive control (induced) animals receive 2 ml of 4% (v/v) acetic acid. group 3 with Lower extract of PHPE - 500mg/kg dose, group 4 was treated group with higher extract of PHPE-1000 mg/kg dose & group 5 standard group received 2 ml of 4% (v/v) acetic acid along with Prednisolone (2 mg/kg p.o). Animals will be pretreated with extract for 7 days. On the 8th day acetic acid induced, continuously treatment for 3 days. After 48 hours animals will be sacrificed by cervical dislocation and dissected to remove colon. Waste material will be removed from colon and it will be flushed with saline gently.

**Recording of changes in the body weight**

Body weight of all experimental animals was recorded before the beginning of animal experimentation and *post* experimentation, after the last dose.

**Dissection, scoring and estimations.**

At the end of experimental protocol, abdomen was opened and colon exposed. The distal 8cm of the colon was opened by longitudinal incision. After cleaning colon of fat and mesentry, was cut into three pieces for macroscopic, microscopic assessment of colonic damage and biochemical estimation.

Scoring of inflamed colons of experimental animals of acute model of colitis [13] Macroscopic colonic damage assessment for visible damage as described by Bell *et al*., by an observer blind to treatment protocol.

**Biochemical estimations**

Colonic tissue sample was be homogenized, centrifuged and in resultant supernatant was subjected to estimation of colonic MPO activity [14] for quantifying inflammation) MDA [15] as described.

**Estimation of Myeloperoxidase [MPO]in the Colon tissue.**

MPO activity, marker of neutrophil infiltration was performed as follows: Pieces of inflamed tissues (rat colon- 2 cm/rat ileum-2 cm) was rinsed with ice-cold saline, blotted dry, weighed and excised. Minced tissue was homogenized in 10 volumes of ice-cold potassium phosphate buffer (pH7.4), using tissue homogenizer. The homogenate was centrifuged at 10000rpmfor 30 min at $4^oC$. Supernatant collected was mixed with *o*-phenylenediamine (660 mg/ml) in phosphate buffer and 300 mM $H_2O_2$ was used to initiate the reaction. Absorbance was observed at 492 nm at an interval of 30 seconds for 5 min. One unit of MPO activity is defined as the change in absorbance per minute by 1.0 at room temperature, in the final reaction.

Calculation of MPO activity

$$\text{MPO activity (U/g)} = \frac{X}{\text{Wt. of the piece of tissue taken}}$$

$$\text{Where } X = \frac{10 \times \text{change in absorbance per minute}}{\text{Volume of supernatant taken in the final reaction}}$$

**Estimation of lipid peroxidation in the Colon tissue.**

The level of lipid peroxides was estimated by Thio barbituric acid reaction method as described by Ohkawa *et al.* Briefly, to 0.2 ml of test sample, 0.2 ml of SDS, 1.5 ml of acetic acid and 1.5 ml of TBA were added. The mixture was made up to 4 ml with water and then heated in a water bath at 95°C for 60 minutes. After cooling, 1 ml of water and 5 ml of n- butanol /pyridine mixture was added and shaken vigorously. After centrifugation at 4000 rpm for 10 minutes, the organic layer was taken and its absorbance was read at 532 nm. The level of lipid peroxides was expressed as n moles of MDA released/ g wet tissue.

| Reagents | Sample | Blank |
|---|---|---|
| SDS | 0.2 ml | 0.2 ml |
| Supernatant | 0.2 ml | …… |
| DDW | 1.6ml | 1.8 ml |
| Acetic acid | 1.5 ml | 1.5ml |
| TBA | 1.5 ml | 1.5ml |
| n-butanol/pyridinemix | 5ml | 5ml |

$$\text{Concentration of MDA} = \frac{\text{Absorbance at532 nm}}{\text{Lx?}} \text{ x D}$$

Where,

L:lightpath (1cm).

?: Extinction coefficient1.56x105M-1.Cm-1.

$$\text{D: dilution factor} = \frac{\text{Total volume (10ml)}}{\text{Volume of the sample (0.2ml)}}$$

## Statistical Analysis

Allvalues were expressed as mean±SEM and subjected to statistical analysis namely, one-way Analysis of variance (ANOVA) followed by Tukey's post test using Graph Pad Prism 8.0.
Values of P <0.5 and less was considered statistically significant.

## Result & Discussion

**Acute Colitis Model:** Effect of extract treatment on the body weight of animals. Effects of increasing doses of extract on the bodyweight of animals are as shown in the table- 1 and represented as figure-1. No significant difference between various groups of animals exists on day zero. All experimental animals recorded reduction in body weight at the end of study compared to weight on day zero. By day 12$^{th}$ significant difference between body weights of treatment groups compared to vehicle treated pathogenic groups of animals was observed.

**Table1: Effect of polyherbal plants extracts on body weight of experimental animals before and after test protocol**

| Group | Treatment | Weight of animals [in grams] | |
|---|---|---|---|
| | | Day0 | Day12 |
| I | **Normal** | 170.0±8.36 | 171.0±9.13 |
| II | **Positive Control** | 170.0±11.40 | 164.2±10.54 |
| III | **PHPE Lower Dose(500 mg/kg)** | 187.0±17.44 | 183.0±14.11$^{*}$ |
| IV | **PHPE Higher Dose (1000 mg/kg)** | 212.0±9.02 | 199.0±8.86$^{**2}$ |
| V | **Prednisolone (2mg/kg)** | 211.0±6.78 | 204.0±6.96$^{**1}$ |

**All value are mean ± SEM of n=5 One way ANOVA followed by Tukey's post-test.** Comparison Test. $^{**1}$P<0.01Vs Positive control on day12,$^{**2}$P<0.01VsPositive control on day12,*P<0.01Vs Pathogenic on day 12.

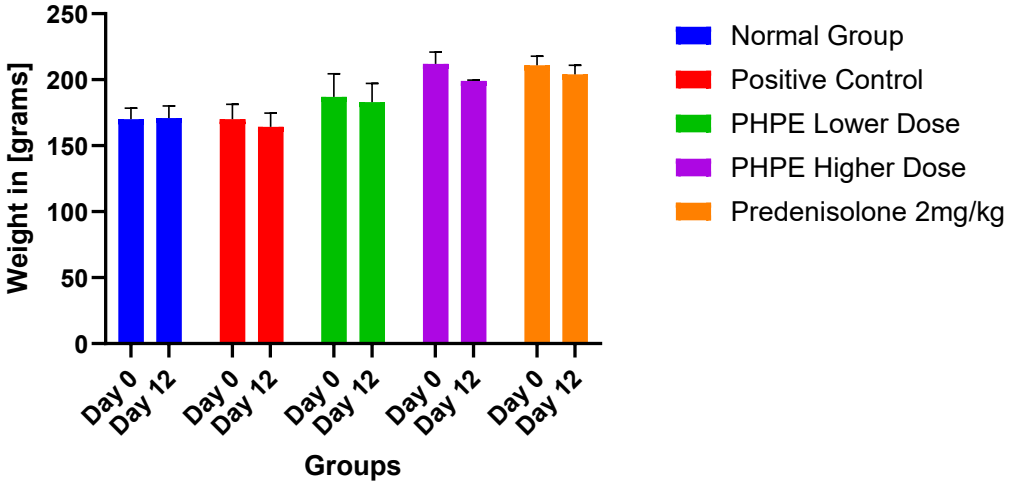


**Fig-1: Body weight of experimental animals before and after test protocol (Acetic Acid Induced Colitis)**

No statistically significant difference in body weight between experimental animals was recorded of day zero, as well as day twelve.

**Effect of polyherbal plants extracts treatment on histopathological changes / macroscopic changes of inflamed colon score:**

Table represents significant reduction in macroscopic score value compare to acetic acid alone. Each value represents mean of macroscopic scores ± S.E.M.(n=6). Signification macroscopic score values according to one-way ANOVA followed by Tukey's post-test, when compare with positive control group $^{x}$ P<0.01 Vs PHPE (Lower Dose) & compare with x P<0.001 PHPE (Higher Dose) & Prednisolone 2mg/kg.

**Table2: Effect of PHPE treatment on histopathological changes [Macroscopic scoring for inflammation]**

| Group | Treatment groups | Score |
|---|---|---|
| 1 | **Normal** | 0 |
| 2 | **Positive Control** | 10.16± 0.41 |
| 3 | **PHPE Lower Dose (500mg/kg)** | 6.68±0.82$^{*}$ |
| 4 | **PHPE Higher Dose(1000mg/kg)** | 2.84±0.47$^{x}$ |
| 5 | **Prednisolone (2mg/kg)** | 2.16±0.18$^{x}$ |

Table represents significant reduction in macroscopic score value compare to acetic acid alone. Each value represents mean of macroscopic scores ± S.E.M.(n=6). Signification macroscopic score values according to one-way ANOVA followed by Tukey's post-test, when compare with positive control group $^{x}$ P<0.01 Vs PHPE (Lower Dose) & compare with x P<0.001 PHPE (Higher Dose) & Prednisolone 2mg/kg.

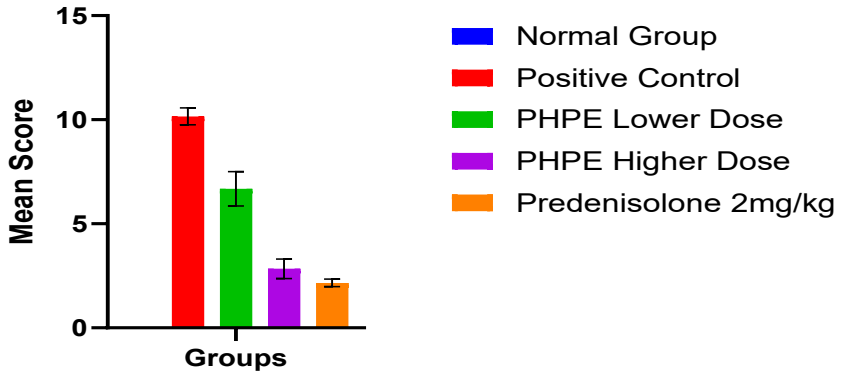


**Fig-2: Effect of PHPE treatment on macroscopic scoring of Colon. (Acetic Acid Induced Colitis)**

**Effect of Polyherbal plants extract treatment on histopathological changes [Macroscopic scoring for inflammation]**

| | | | | |
|---|---|---|---|---|
| | | | | |
| **Figure-1** | **Figure-2** | **Figure-3** | **Figure-4** | **Figure-5** |
| **Normal Group** | **Positive Control** | **PHPE Lower Dose-500mg/kg** | **PHPE Higher Dose-1000mg/kg** | **Prednisolone 2mg/kg** |

**Microscopic assessment [Histopathology] report of Acetic Acid induced Colitis in Rats.**

| | |
|---|---|
| 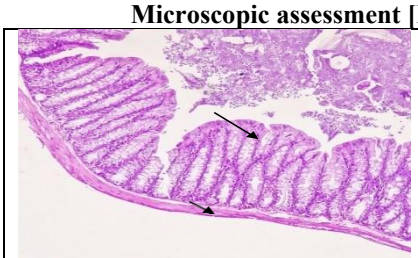 | Normal Group: Section studied from the colon shows intact mucosa lined by glandular epithelium with intact submucosal layer. The goblet cells in the mucosa appear intact. The muscular layer and serosal layer appear unremarkable. |
| 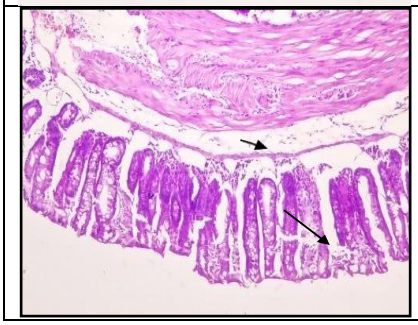 | Positive Control Group: Section studied from the colon shows focal ulceration and areas of necrosis within the mucosa. The goblet cells appear reduced compared to normal control. The mucosal layer is infiltrated by mixed inflammatory cells predominantly comprising of lymphocytes, neutrophils and macrophages. The sub mucosal layer shows moderate edema with moderate mononuclear inflammatory infiltration. The muscular and serosal layers appear unremarkable. |

| | |
|---|---|
| 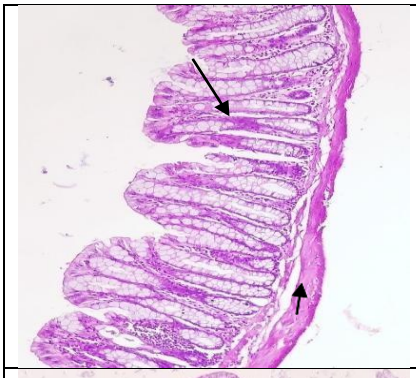 | Extract (Lower Dose) Section studied from the colon shows intact mucosa lined by glandular epithelium with mild edema of sub mucosal layer. The goblet cells appear intact compared to normal control. The mucosal layer is infiltrated by moderate mononuclear inflammatory cells predominantly comprising of lymphocytes and macrophages. The muscular and serosal layer appears unremarkable. |
| | Extract (Higher Dose) Section studied from the colon shows intact mucosa lined by glandular epithelium. Long with intact sub mucosal layer. The goblet cells appear intact compared to normal control. The mucosal layer is infiltrated by mild mononuclear inflammatory cells predominantly comprising of lymphocytes and macrophages. The muscular and serosal layer appears unremarkable. |
| 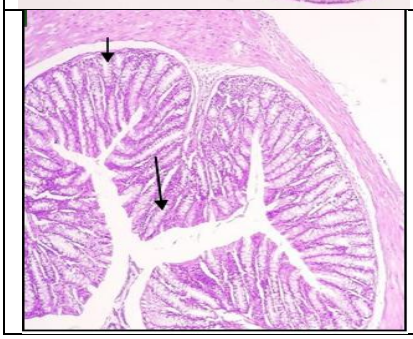 | Prednisolone standard dose: Section studied from the colon shows intact mucosa lined by glandular epithelium with mild edema of sub mucosal layer. The goblet cells appear intact compared to normal control. The mucosal layer is infiltrated by mild mononuclear inflammatory cells predominantly comprising of lymphocytes and macrophages. |

**Table 3: Effect of Polyherbal plant extracts treatment on MPO & LPO Values.**

| Groups | Treatment Groups | MPO activity (U/g) ± S.E.M | LPO Activity (µmol/g) S.E.M |
|---|---|---|---|
| I | Normal | 2.67±0.21 | 0.20±0.04 |
| II | Positive Control | 12.83±0.87* | 0.77±0.05* |
| III | PHPE Lower Dose (500 mg/kg) | 7.83±0.87b | 0.38±0.09b |
| IV | PHPE Higher Dose(1000mg/kg) | 2.50±0.56 c | 0.20±0.03c |
| V | Prednisolone (2mg/kg) | 1.50±0.22 c | 0.13±0.02 c |

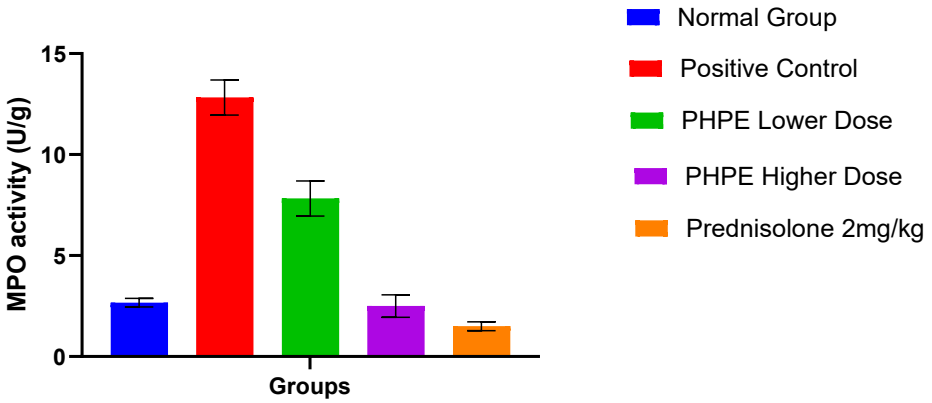


**Figure 3: Effect of Polyherbal plant extracts treatment on MPO Values**

**Effect of PHPE on MPO:** The myeloperoxidae assay showed significantly increase level of MPO activity Normal to Positive Control group *P<0.001, When compare to PHPE (Lower Dose) Vs Positive Control group b P<0.01, When

compare with Positive control Vs PHPE (Higher Dose) c P<0.001, When compare with Positive control Vs Prednisolone (2mg/kg) c P<0.001.

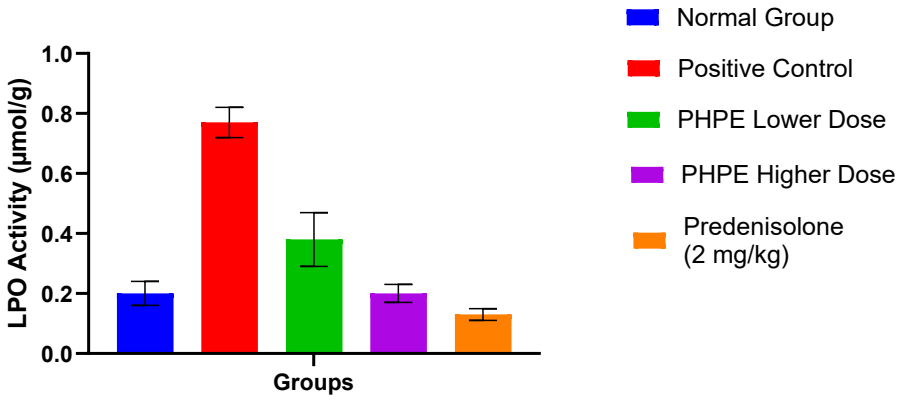


**Figure 4: Effect of Polyherbal plant extracts treatment on LPO Values**

**Effect of PHPE on LPO:** The Lipid Peroxidase assay showed significantly increase level of LPO activity Normal to Positive Control group *P<0.001 When compare to PHPE (Lower Dose) Vs Positive Control group b P<0.01, When compare with Positive control Vs PHPE (Higher Dose) c P<0.001, When compare with Positive control Vs Prednisolone (2mg/kg) c P<0.001.

## CONCLUSION

These Phytochemical compounds of *Hemidesmus indicus* roots & *Centratherum anthelminticum* seeds have been found to induce a wide spectrum of activities such as reduction in oxidative stress, suppression of inflammation, and cell proliferation.On the basis of the results obtained in the present study, it is concluded that an methanolic extracts of roots of Hemidesmus indicus & Centratherum anthelminticum exhibits high antioxidant and free radical scavenging activities & extract have potent protection against acetic acid induced ulcerative colitis.

## REFERENCES

1. Buffinton GD, Doe WF. Depleted mucosal antioxidant defences in inflammatory bowel disease. Free Radic Bio Med 1995; 19: 911-8.
2. Koch TR, Yuan LX, Stryker SJ, Ratliff P, Tel ford GL, Opara EC. Total antioxidant capacity of colon in patients with chronic ulcerative colitis. DigDisSci2000; 45:1814-9.
3. Mulder TP, Verspaget HW,Janssens AR, deBruin PA, Pena AS, Lamers CB. Decrease in two intestinal copper/Zn containing proteins with antioxidant function in inflammatory bowel disease. Gut 1991; 32: 1146-50.
4. Fantone JC, Ward PA. Role of oxygen derived free radicals and metabolites in leucocyte- dependent inflammatory reactions.AmJPath1982;107:395-418.
5. FloheL, Beckmann R, Giertz H, Loschen G. Oxygen-centred free radicals as mediators of Inflammation in oxidative stress, SiesH(ed)London,AcademicPress1985;PP403-36.
6. KaserA,Zeissig S,Blumberg R S. Inflammatory Bowel Disease. Annu Rev Immunol 2010;28:573–621.
7. Rajan S, Shalini R, Bharathi C, Aruna V, Elgin A, Brindha P. Pharmacognostic and Phytochemical studies on Hemidesmus indicus root. International Journal of Pharmacognosy and Phytochemical Research 2011; 3:74-9
8. Saravanan N, Nalini N. Antioxidant effect of Hemidesmus indicus on ethanol induced hepatotoxicity in rats. J Med Food 2007; 10:675-82.
9. Khandelwal VK, Balaraman R, Pancza D, Ravingerova T. Hemidesmus indicus and Hibiscus rosa-sinensis affect Ischemia reperfusion injury in isolated rat hearts. Evid Based Complement Alternal Med 2011. doi: 10.1155/2011/802937
10. Kirtikar KR, Basu B D.IndianMedicinal Plants,Dehradun; International book distributers1975.
11. Ashok P, Koti BC, Thippeswamy AH, Tikare VP, Dabadi P, Viswanathswamy AH. Evaluation of anti-inflammatory activity of Centratherum anthelminticum (L) Seed. Indian J Pharm Sci 2010; 72: 697-703.
12. Tian G, Zhang U, Zhang T, Yang F, ItoY. Separation of flavonoids from the seeds of Centratherum anthelmintica (L) Willd by high speed counters current chromatography. J Chromatogr A 2004; 1049: 219-22.
13. Bell CJ,Gall DG,Wallace GL.Disruption of colonic electrolyte transport in experimental colitis. AmJ Physiol1995; 268:G622-30.
14. Krawisz JE, Sharon P,Stenson WF.Qualitative assay for acute intestinal inflammation based on myeloperoxidase activity. Assessment of inflammation in rat and hamster models. Gastroenterology 1984; 87: 1344-50.
15. Ohkawa H, Ohishi N, Yagi K. Assay of lipidperoxidase in animal tissues by thiobarbituricacid reaction. AnalBiochem1979;95:351-8.